



Discovery MR750 3.0T Elevates Clinical Utility of High-Resolution Imaging of the Cranial Nerves




By Peter Lavery, Lead MR Radiographer and Mitesh Ghandi, MD, neuroradiologist, Queensland X-ray

When a patient presents to a specialist with a nerve related ailment, whether it be cranial or peripheral, high-resolution imaging of the cranial nerves is used to help pinpoint and diagnose conditions accurately and efficiently. The overwhelming response to MRI's effectiveness in this area has led to a surge in interest over the last few years.

At Queensland X-ray (QLD X-Ray), MR Neurography is primarily used to investigate the cranial nerves. Clinical literature describes MR Neurography as using T2-weighted FSE sequences with ultra-long TEs, which depicts bright abnormal nerves in a relatively dark background. The technique produces high-resolution images of the cranial nerves and their anatomical pathways by generating extremely thin slices in multiple planes with multiple contrast weightings. Historically, this led to lengthy scan times, which often results in image artifacts and poor image

quality due to patient movement, and, therefore, the technique was not routinely used in clinical practice.

With the introduction of the Discovery MR750 3.0T from GE, our radiologists and referring doctors can now successfully apply this new frontier in neuroimaging. The Discovery MR750 allows us to scan patients at a greater speed with high resolution isotropic 3D sequences that can be reformatted in multiple plans and variable slice thickness. Previously, acquiring images in 3D caused a decrease in contrast, compared to 2D, with variability in image quality when using fat saturation techniques. However, a new technique on the Discovery MR750 that couples a 3D FSPGR with IDEAL helps overcome prior imaging limitations in MR Neurography. The combination of improved speed and new technique now enable our radiologists to view fine details of the cranial nerves and small branches for a more accurate depiction





of the extent of neuro pathology, such as perineural spread of skin cancers along the cranial nerves and the detailed anatomical extent of tumors in the skull base – the later two being the most common indications for the use of this technique at QLD X-Ray. This accurate depiction of the tumor, its branches and relationship to vital adjacent soft tissue structures in the skull base enables the surgeon to more effectively tailor surgery to the individual patient.

Clinical case

Patient history

The patient was diagnosed with a pleomorphic adenoma in the right carotid, which was surgically excised at age 13 followed by radiotherapy. In 2001, at age 47, he presented to the specialist with loss of hearing and tingling in the right side of the face. Clinical examination revealed a tumor in the right external auditory canal. Further MR image reviews indicated a large tumor mass in the para pharynx extending up through the jugular foramen, into the middle ear, and then into the posterior cranial fossa. It completely surrounded the facial nerve and sat close to the hypoglossal canal, extending towards the foramen magnum. Histology proved the tumor to be a carcinoma ex pleomorphic (a malignant tumor that is believed to develop from some benign pleomorphic adenomas after many years).

The patient had near total removal of the tumor and a free-flap reconstruction with post operative radiotherapy. In 2005, he had further recurrence of the tumor in the jugular bulb and the lower aspect of the cerebellopontine angle. Biopsy determined this to be a benign pleomorphic adenoma. At this stage the patient had thrombosed his right internal carotid artery – possibly related to a combination of radiotherapy and surgery.

Technique

The patient was scanned using the 8-channel HD Brain coil from GE Healthcare.

The acquired protocol consisted of a coronal T2 FS IDEAL and axial T1 and T2 FS IDEAL sequence performed pre-contrast.

This was complemented by an axial 3D FSPGR IDEAL sequence, reconstructed in three planes (1 mm/1 mm).

This sequence is described in Table 1.

Table 1. Axial IDEAL FSPGR + Contrast

Field of View (FOV)	180 mmw
Imaging matrix	256x256
Slice thickness	1 mm
Repetition time (TR)	6.7 ms
Echo time (TE)	Min TE
Frequency	A/P
Flip angle	12
NEX	1
Slice resolution	95%
Imaging options	ASSET (2); IDEAL; Zip 512; Zip 2; EDR
Scan time	3 min



Peter Lavery

Peter Lavery, MRI radiographer at Queensland X-ray and MRI supervisor at the Mater Private Hospital, Brisbane, holds a Level 2 Accreditation with the Australian Institute of Radiography. He has supervised MR imaging departments in London and Dublin, and is currently involved in several research projects at the University of Queensland while pursuing his Masters Degree, including "Phosphorous Spectroscopy of the Calf Muscle During Exercise" and "MRI of Adolescent Idiopathic Scoliosis." Lavery is a published author on MRI imaging of scoliosis in *The Radiographer*, an Australian peer-reviewed radiology journal.



Dr. Mitesh Ghandi

About the facility

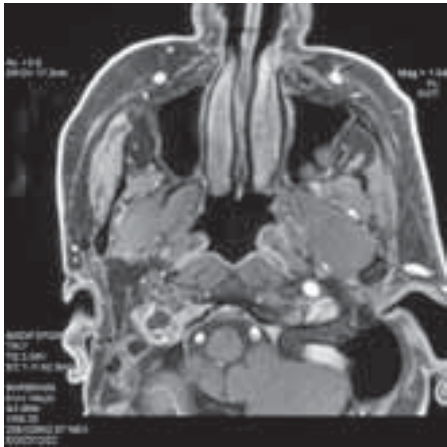The Mater Private site on the south bank of Brisbane, Queensland, is the busiest of approximately 40 radiology sites for Queensland X-Ray. This multi-modality practice features the most technologically advanced equipment in Brisbane and includes 3.0T MRI, two multi-slice CT scanners and a new PET CT facility. The facility's niche is in neuroimaging.

In March 2009, Queensland X-Ray installed the first Discovery MR750 3.0T MRI system in the Southern Hemisphere and continues to explore the system's potential, particularly in the neurological field. Backed by some of the best radiologists in Queensland, including Dr. Mitesh Ghandi and Dr. Robert Clarke, and an enthusiastic team of MRI radiographers, Queensland X-ray is achieving incredible MR imaging results.

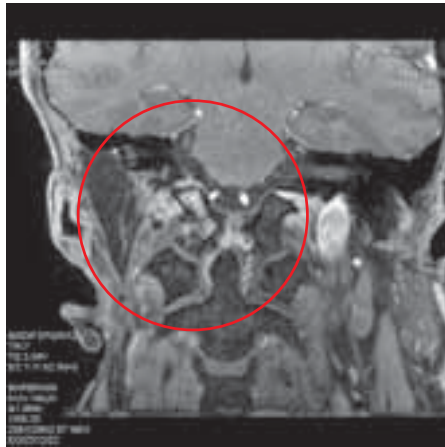We are visualizing nerves we've never seen before.

Dr. Mitesh Ghandi

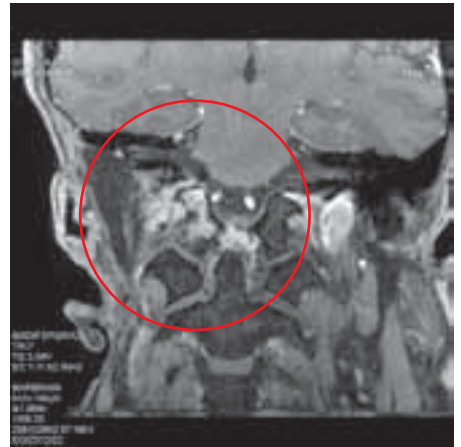



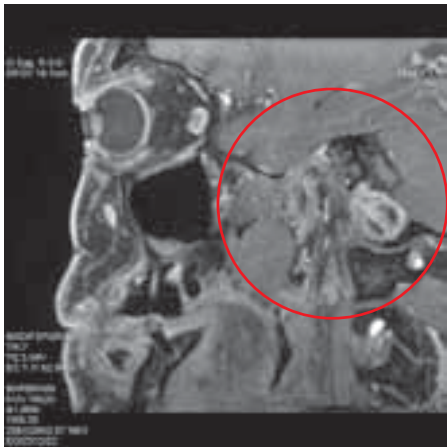Post Contrast – 3D IDEAL



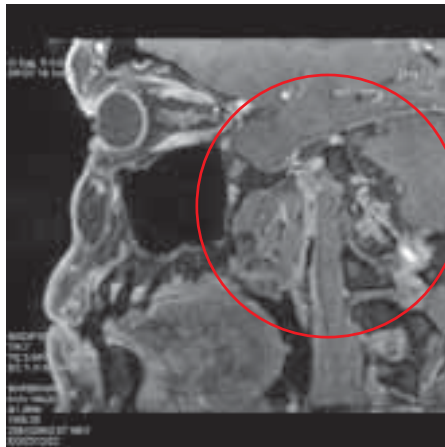Coronal Reformat – 3D IDEAL



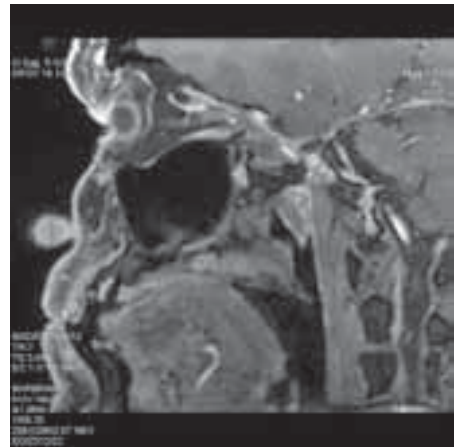
Coronal Reformat – 3D IDEAL



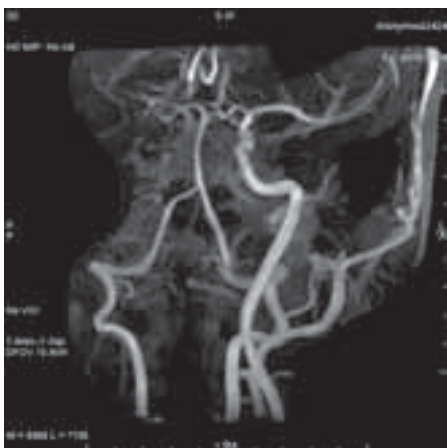Sagittal Reformat – 3D IDEAL



Sagittal Reformat – 3D IDEAL



Sagittal Reformat – 3D IDEAL



MRA of the neck vessels. Data extracted from the 3D IDEAL data set. Note the missing right carotid vessel.

Diagnosis

Currently the patient has residual tumor in the jugular foramen, infiltrating the hypoglossal canal and extending towards the clivus. This sits above and anterior to his right vertebral artery. Given that he no longer has a right internal carotid artery, his right hemisphere is predominately supplied by the right vertebral. The case is currently with the interventional radiologist to consider whether it is theoretically possible to sacrifice the vertebral should it be damaged in further removal. The latest MRI suggests that the tumor has infiltrated the bony margins of the jugular foramen bone indicating malignancy – Carcinoma ex pleomorphic adenoma. ■

