

Cancer Detection Improves for Women with Dense Breasts When Automated Breast Ultrasound Screening is Combined with 3D Tomosynthesis

Introduction

When Ohio passed the breast density notification law in December 2014, MetroHealth Medical Center at Case Western Reserve University was using the combination of 2D digital mammography and 3D tomosynthesis as their standard screening protocol. The new legislation became the driving force for selecting Invenia™ Automated Breast Ultrasound (ABUS) as a supplemental screening tool for women with dense breasts.

MetroHealth has been using the 2D and 3D tomosynthesis screening combination for several years. In November 2014, they performed their first ABUS exam. Over the next six months they offered ABUS to all women identified as having dense breasts. ABUS was performed on 689 of these patients.

Reviewing the seven-month period from November 14, 2014 through June 1, 2015, during which time they used ABUS as a complement to 2D and 3D tomosynthesis screening, MetroHealth was able to detect four small, early-stage cancers in the 689 asymptomatic, dense breast women for whom 3D tomosynthesis findings were normal or benign. The staff at MetroHealth determined that a multi-modality approach would help ensure that dense breast patients are imaged comprehensively. The results justified the continued use of ABUS.

MetroHealth's radiologists found ABUS easy to integrate into their screening workflow. The automated imaging process is easy for the technologists to perform, and the 3D volumes provide uniform, high-resolution images as well as reproducibility from operator to operator. Additionally, they can archive ABUS 3D volumes so that subsequent exams can easily be compared.

While tomosynthesis has been found to detect the majority of cancers in women with dense breasts, the following case studies suggest the added benefit of including automated breast ultrasound as a screening option.

"By adding ABUS to our standard screening protocol, we were catching small, early-stage cancers we would have otherwise missed. That was interesting to us, because most of the current studies for ABUS combined it with 2D imaging only. With the integration of the ABUS technology, we were able to give our patients a better outcome and a chance for a possible cure."

– Dr. Christina Clemow, Section Chief of MetroHealth's Division of Breast Imaging and Intervention.

Case Studies

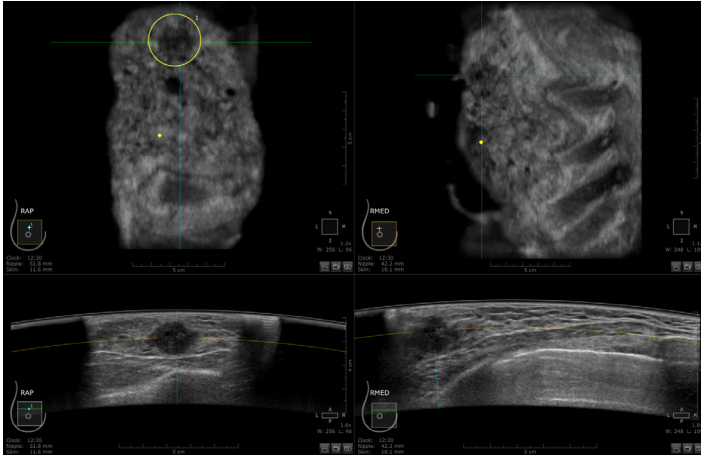
In the following cases, the patients were given 2D mammograms and tomosynthesis plus ABUS screenings. While tomosynthesis provided a 3D view of dense breast tissue, it did not demonstrate any significant abnormalities in these cases. The ABUS screenings detected small mammographically occult masses in each woman at early stages of development, often providing an earlier diagnosis and sometimes permitting a less invasive treatment plan.



Case Study 1

Presentation

A healthy 47-year-old female had not had a screening mammogram for two years. The earlier mammogram was negative. While the combination 2D and tomosynthesis screening protocol detected no abnormalities, the patient was diagnosed with extremely dense breasts and was offered ABUS. Her personal medical history was positive for a family history of breast cancer.



Multi-volume correlation between the right anterior-posterior and right medial views allows for efficient cross correlation of this invasive, moderately differentiated ductal carcinoma.

Investigation and Diagnosis

ABUS detected a right breast irregular hypoechoic mass with indistinct margins at the 12:30 o'clock position, 4 cm from the nipple. A handheld targeted ultrasound confirmed a 1.6 x 1.3 x 2.2 cm mass. An ultrasound-guided core biopsy was performed and yielded invasive, moderately differentiated ductal carcinoma.

Treatment

The patient underwent a bilateral mastectomy with immediate reconstruction. During the final pathologic evaluation of the mastectomy specimen, a second area of concern was found approximately 1 cm from the primary mass. The patient was referred to oncology and started on tamoxifen.

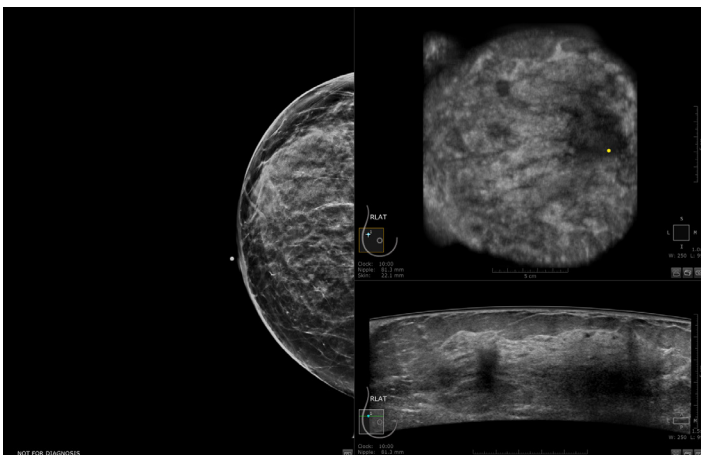
Discussion

Due to the negative results from her routine screening, this patient may have waited another two years before her next screening. MetroHealth's new protocol to offer ABUS to all women with dense breasts allowed the patient to receive an early diagnosis and necessary surgery to treat her cancer.

Case Study 2

Presentation

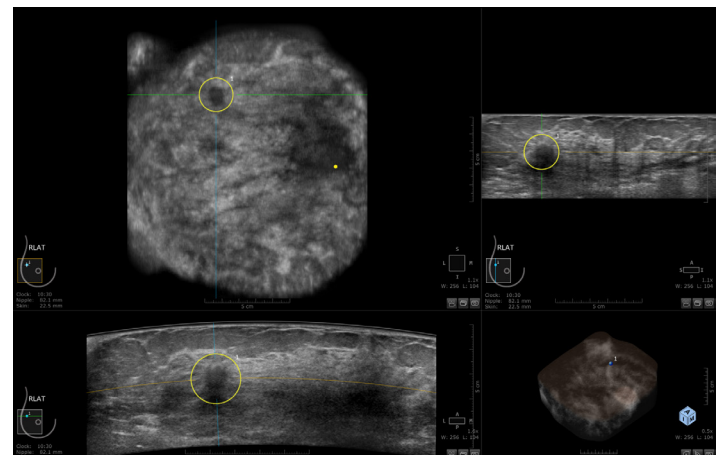
A 52-year-old female with tetraplegia from a motor vehicle accident presented without any additional significant personal medical history or family history of cancer. During her routine screening, her tetraplegia limited positioning of the breast on the mammogram. The mammogram read as negative. The patient was offered an ABUS exam due to her heterogeneously dense breast tissue.



Comparison of normal mammogram and transverse ABUS image

Investigation and Diagnosis

ABUS detected a right breast irregular hypoechoic mass with angular margins and posterior acoustic shadowing at the 10:30 o'clock position, measuring 1.5 x 1.6 x 1.1 cm, 7 cm from the nipple. Dedicated handheld ultrasound confirmed the mass. A core biopsy was performed and detected invasive moderately differentiated ductal carcinoma.



The 3-on-1 hanging protocol allows for multi-planar correlation between the 3 orthogonal views of this biopsy-proven invasive moderately differentiated ductal carcinoma.

Treatment

The patient consented to a lumpectomy and sentinel node biopsy. The patient was referred to medical oncology for adjuvant chemotherapy.

Discussion

Physical disabilities can limit positioning with mammography and result in insufficient screening data. The Reverse Curve™ transducer used with ABUS offers enhanced breast coverage and enables a technician to perform a comprehensive screening with the patient lying on her back. In this case, the patient was able to get an accurate diagnosis and treatment before the cancer advanced to a higher stage.

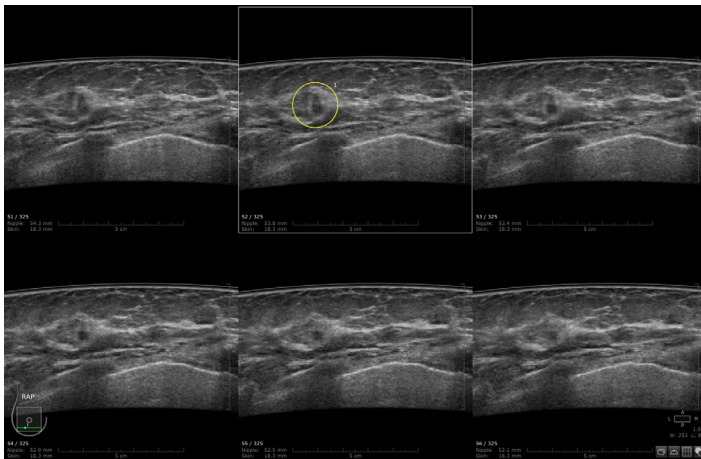
Dense breasts defined

- Breasts are classified as dense if fibroglandular tissue makes up more than 50 percent of their volume.
- Women with dense breast tissue have a 4 to 6 times higher risk of developing breast cancer than women with minimal fibroglandular tissue in their breasts.¹

Case Study 3

Presentation

A 58-year-old female presented for an overdue mammogram. It had been six years since her previous screening. The patient had a personal history of smoking and a family medical history that included a maternal aunt with breast cancer. She was offered ABUS due to heterogeneously dense breasts.



The multi-slice hanging layout demonstrates this biopsy-proven, invasive poorly differentiated ductal carcinoma in situ, comedo variant with size and location intervals.

Investigation and Diagnosis

ABUS detected a right breast irregular hypoechoic mass with indistinct and angular margins at the 7:30 o'clock position, 5 cm from the nipple. Dedicated handheld ultrasound confirmed the mass and its sub-centimeter size of 8 x 5 x 7 mm. Final pathology resulted in invasive, poorly differentiated ductal carcinoma of the breast with a background of high-grade nuclear ductal carcinoma in situ, comedo variant.

Treatment

The patient underwent a right partial mastectomy that confirmed a stage IA diagnosis. Since the tumor was discovered when it was below 1 cm in size and the patient had negative ER and PR status, she was not a candidate for adjuvant systemic chemotherapy. However, she did require radiation therapy.

Discussion

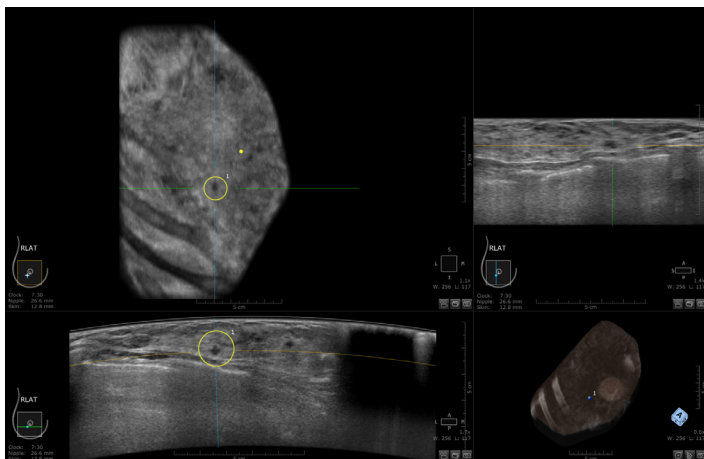
Thanks to the ABUS exam, the patient's cancer was detected at a fairly early stage and systemic chemotherapy was not required. Detection of the breast cancer resulted in a subsequent diagnosis of lung cancer during an oncology workup. She was treated with chemotherapy and radiation for the lung cancer.

Case Study 4

Presentation

A 63-year-old woman had noticed a palpable mass in the right axilla, which she described as waxing and waning over several years. The axillary mass seemed to have grown in size but her previous year's mammogram was negative.

An open biopsy was performed by a plastic surgeon and revealed invasive adenocarcinoma with a suspected primary breast carcinoma.



The 3-on-1 hanging protocol allows for multi-planar correlation of this invasive ductal carcinoma and high grade solid-type ductal carcinoma in situ.

Investigation and Diagnosis

A diagnostic 2D mammogram and tomosynthesis demonstrated no significant abnormalities. The patient was noted to have dense breasts and ABUS was used to search for the biopsy-proven, mammographically occult cancer. ABUS detected a right irregular hypoechoic mass with indistinct and angular margins at the 7:30 o'clock position, 2.5 cm from the nipple. Diagnostic handheld ultrasound identified the mammographically occult mass measuring 6 x 4 x 4 mm. An ultrasound-guided core biopsy diagnosed invasive ductal carcinoma and high nuclear grade solid-type ductal carcinoma in situ. The patient was a clinical stage IIIC. This cancer was confirmed with subsequent MRI investigation.

Treatment

The patient underwent breast conservation surgery with axillary node dissection. She required adjuvant chemotherapy and chest wall radiation.

Discussion

Without ABUS, the early developing cancer would have remained undetected via mammogram. ABUS allowed confident identification of a small mammographically occult cancer allowing early and immediate diagnosis and appropriate treatment.

Dr. Christina Cavalier Clemow, D.O.



Dr. Clemow is a diagnostic radiologist and the Section Chief of the Division of Breast Imaging and Intervention at MetroHealth Medical Center, Case Western University in Cleveland, Ohio. She initiated the ABUS program in reaction to Ohio's 2014 breast density notification law and presented her findings at RSNA 2015.

Dr. Clemow earned her medical degree from Lake Erie College of Osteopathic Medicine. She completed her Diagnostic Radiology Residency and attended Diagnostic and General Surgery Residencies at the University of Florida Shands in Jacksonville, Florida. She did a Fellowship in Breast Imaging and Intervention at MetroHealth Medical Center in Cleveland. She is board-certified by the American Board of Radiology and authorized-user-eligible in nuclear medicine.

Summary

The MetroHealth review provides strong evidence for using ABUS in combination with tomosynthesis. During the review period, ABUS was well tolerated by participants and was easily incorporated into their practice. The results from their review indicate that these complementary technologies support rather than contradict each other and provide a significant patient population with the opportunity for earlier cancer diagnosis and better outcomes.

If you'd like to learn more about our technology and training, contact your GE Healthcare sales representative for more information, visit www.gehealthcare.com/inveniaabus, or call 866-281-7545.

1. Boyd, et al, NEJM Jan 2007.

Imagination at work

www.gehealthcare.com. Product may not be available in all countries and regions. Contact a GE Healthcare Representative for more information.

Data subject to change.

© 2016 General Electric Company.

GE, the GE Monogram, imagination at work, Reverse Curve and Invenia are trademarks of General Electric Company.

BI-RADS is a trademark of the American College of Radiology. Third party trademarks are the property of their respective owners.

Reproduction in any form is forbidden without prior written permission from GE. Nothing in this material should be used to diagnose or treat any disease or condition. Readers must consult a healthcare professional.

